



SCHARIOTH  
MACULA LENS  
**A45SML**

## THE MAGNIFIER IN THE EYE

THE NEW HOPE FOR PATIENTS WITH DRY AMD

# SCHARIOTH MACULA LENS

MEDINOVĀ

MEDI  NTUR

Vision of Expertise



# WHAT IS SML?

SML is a bifocal Add-On IOL with a specifically designed central optic area providing high addition power of +10.0D, developed by **Prof. Gabor B. Scharioth.\***

SML is intended for monocular implantation in the better-seeing eye, without affecting distance vision or visual field.



- Add-on with simple bifocal design
- Central 1.5 mm diameter optical zone with +10D
- Peripheral zone optically neutral
- Combines proven add-on technology
- With sufficient magnification
- Without affecting distance vision or visual field

# SML . Scharioth Macula Lens

## SML – Features

---

01

Implantation site:  
ciliary sulcus

02

4 flex haptics  
– perfect fit

03

Non-torque design  
– rotational stability

04

Square design  
– no iris capture

05

Convex-concave  
optic – no IOL touch

06

Hydrophilic material  
with very low  
chromatic aberration  
(Abbe 57)

07

Easy and safe  
surgery  
– through 2.2 mm  
incision

08

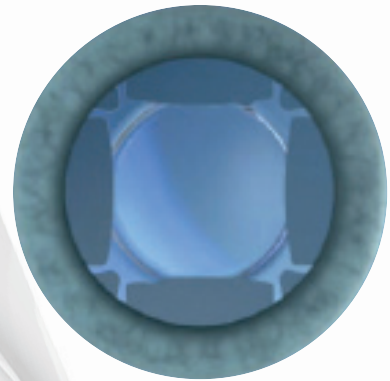
Round polished  
edges  
– no chafing  
effect



## Strengths


---

- Sufficient magnification
- Easy and safe surgery
- Independent from lens status
- No reduction of visual field
- Not affecting distance vision
- Reversibility
- Affordable



## SML is Safe

- **Proven Add-On Platform present on the market since 2010; over 2500 pcs implanted**
- SML is stable in the sulcus
- Without IOP elevation
- No iris capture possible
- No chafing effect



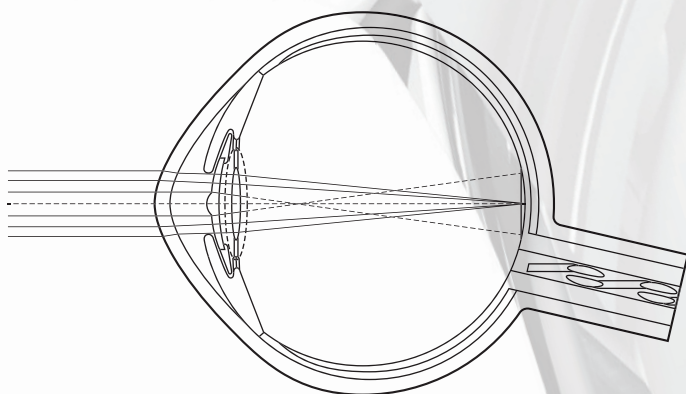
# SML . Scharioth Macula Lens

## Using so – called Near Triad Reflex: miosis – accommodation – convergence

Due to the effect of near vision miosis, the central optical portion - providing the magnified image - will dominate when the patient focuses on near objects only but will not influence far vision significantly when the patient focuses on distant objects through a dilated pupil.

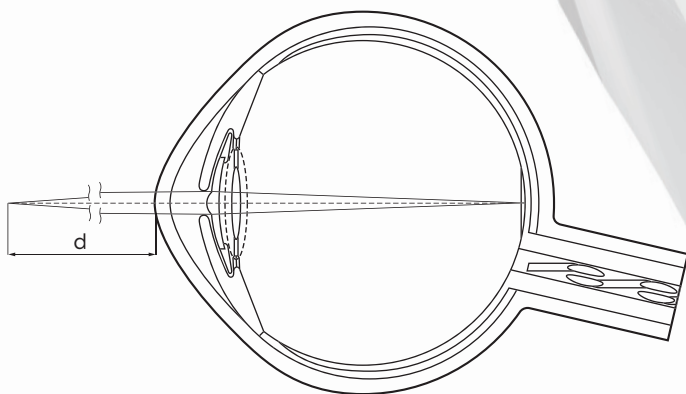
Pict 1: Patient's eye with dilated pupil

- When the patient focuses on a distant object, the pupil is dilated and there is enough space around the central optical region for light rays passing through the peripheral optical portion of the secondary IOL as well.
- Light rays originating from a distant object that pass through the peripheral optical region and form the image of the distant object on the retina (solid lines) will dominate the patient's perception over light rays passing through the central optical region that do not focus on the retina (dashed lines).



Pict 2: Patient's eye with constricted pupil

- When the pupil is constricted, light rays are restricted mainly to the central optical region of the secondary IOL, thus providing a magnified image on the macula. This is the case when the patient focuses on a near object, for example reads a newspaper or a price tag, and the pupil is **constricted due to the near triad reflex**.
- **The image** thus formed **on the retina is magnified** compared to the image formed of distant objects. This feature enables the patient's eye to resolve the image in case of AMD as well.
- Due to the relatively high refraction of the central optical region compared to the basic lens power, sharp vision is achieved at a very near distance (d), which is typically about 15 cm.

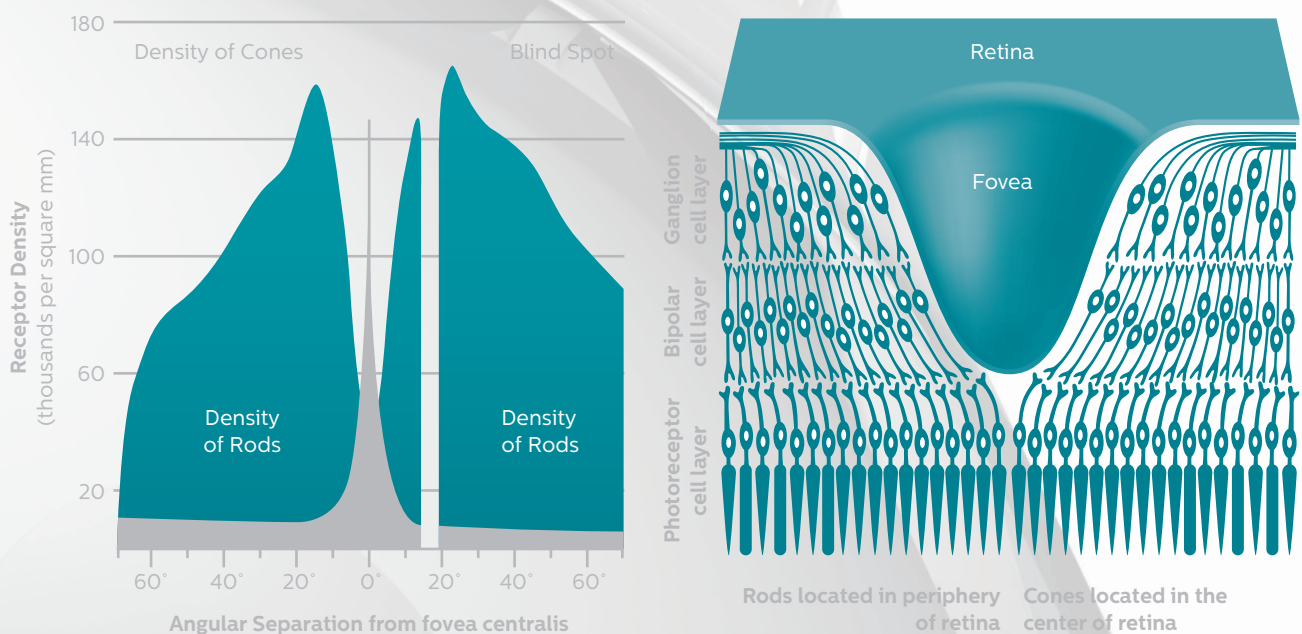


# HOW DOES SML WORK ?



SML uses the best and most sensitive part of retina  
– THE FOVEA – the highest concentration of CONES.

Both color vision and highest visual acuity is attributed to cones.



Cones are concentrated in the fovea. Both color vision and highest visual acuity is attributed to cone cells.

During visual examination of small details, light is focused onto the fovea centralis.

Rods are absent from the fovea but abundant elsewhere in the retina. They are responsible for night vision, our most sensitive motion detection, and our peripheral vision.

Thus, with non-foveal/macular regions of the retina we can detect motion and contours under scotopic conditions but **CANNOT READ IN THE DARK**. That is why **SML does not deflect light away from the fovea**.

SML, by **MAGNIFICATION**, uses the rest of the damaged FOVEA  
– the best and most sensitive part of the retina – to enable reading.

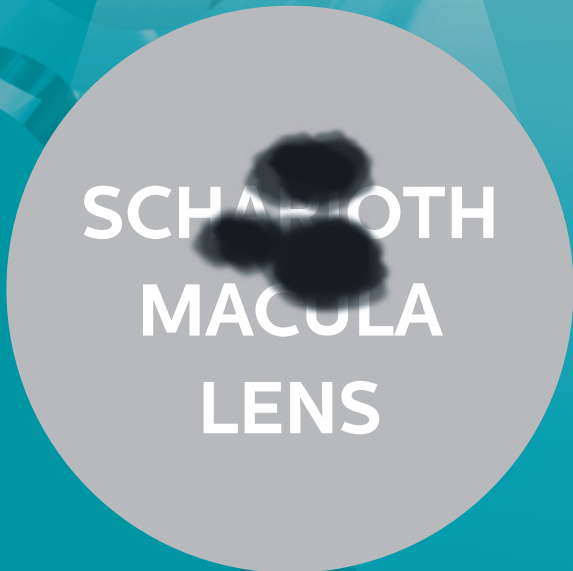
# SML . Scharioth Macula Lens

## Mode of Action: MAGNIFICATION

---

### MAGNIFICATION (about 2-times)

Dark spots covering the text represent damaged macular areas. The SML magnifies the text approximately 2 times but the size of the dark spots remains the same because the SML does not magnify the damaged parts of macula. Thus the SML enables patients with AMD to read the text.



### Enlargement by zooming



With SML



Without SML



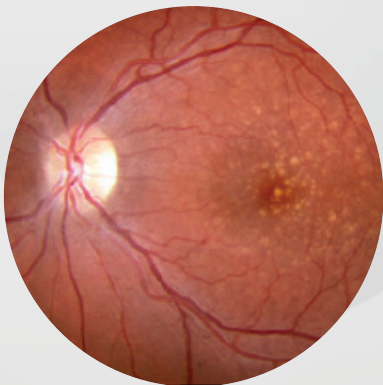

## For whom is SML recommended?

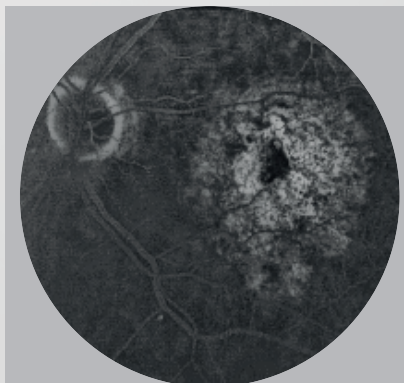
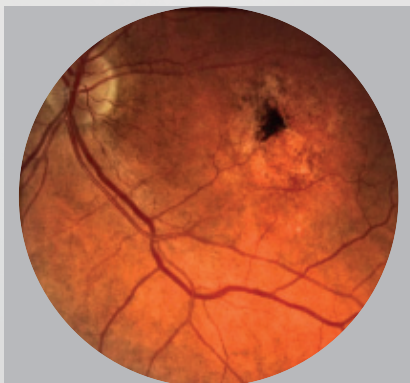- SML targets solely pseudophakic patients with advanced **DRY AMD**, offering them a convenient, simple and safe solution to restore their near vision impaired by AMD.
- **SML - New Technology** focuses on patients with advanced stage AMD but **it might be helpful for patients with other macular diseases** as well, e.g. myopic maculopathy, diabetic maculopathy or hereditary retinal diseases.
- **Two thirds of patients with advanced AMD and visual acuity of 0.3 or less are pseudophakic - these patients might benefit from SML.**

Surgery may be performed simultaneously with cataract surgery, but preferably cataract surgery should be done first and following a repeated postoperative VA testing, SML can be implanted later on if the patient is still dissatisfied.

**THE SML IS POTENTIALLY SUITABLE FOR A LARGE PERCENTAGE OF EYE SURGEONS. NO EXTENSIVE TRAINING IS REQUIRED. THERE IS NO LEARNING CURVE.**



DRY AMD with pathological changes in the retinal pigment epithelium (RPE) and Bruch's membrane (a collagen-rich extracellular matrix between the RPE and choroidal vasculature) including the presence of ophthalmoscopically visible focal yellow deposition of acellular, polymorphous debris called drusen between the retinal pigment epithelium and Bruch's membrane.



**Patient with AMD implanted with SML**

85 old male, single eyed, after 13 intravitreal injections. SML implanted in 2014. Preop BCDVA 0.12, Radner 12 (40 cm and 15 cm). Postop 4 weeks BCDVA 0.12, Radner 4 (sc in 15 cm)  
Courtesy of Prof. Gabor B. Scharioth.

# SML . Scharioth Macula Lens

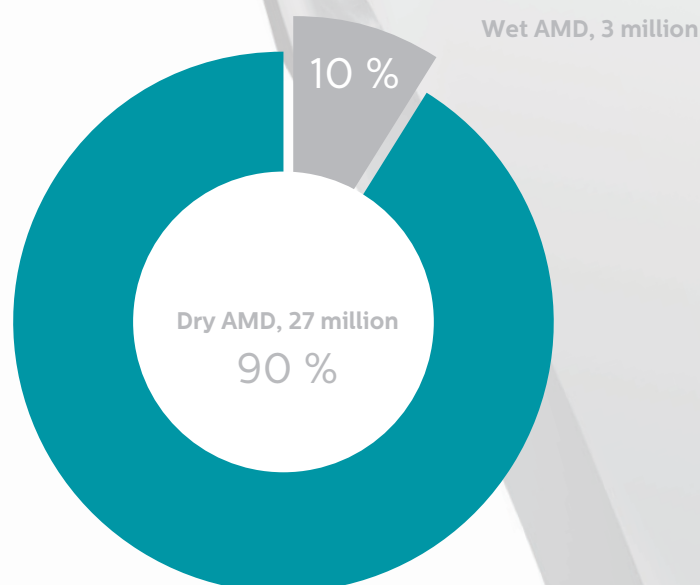
## Almost 30M people worldwide suffer from AMD

Age-related macular degeneration (AMD) affects 8.7 % of the world's population and is the most common cause of **irreversible blindness** in both developed and developing countries, particularly in people older than 60 years.

Its prevalence is likely to increase as a consequence of

- Growth of elderly populations
  - Environmental factors
- Cataract and pseudophakia are the most common eye conditions to be associated with AMD
  - Two thirds of patients with advanced AMD and visual acuity of 0.3 or less are pseudophakic
    - these patients might benefit from SML

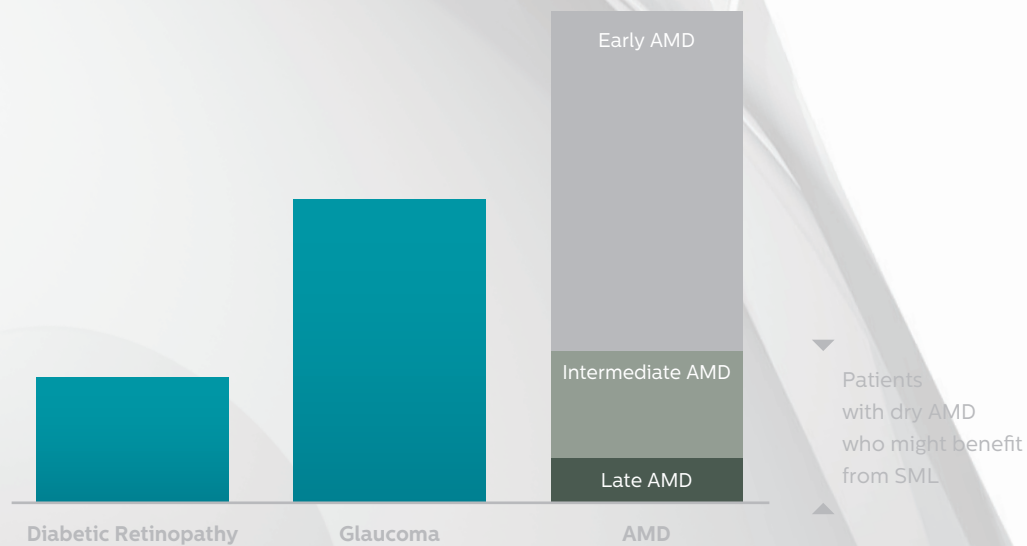
AMD can be generally divided into two types:  
Dry AMD (90–95 %) and Wet AMD (10–15 %)





## AMD is the leading cause of visual impairment in western countries

The most common causes of blindness in developed countries



### Treatment of AMD

There have been significant advances in the management of exudative (wet) AMD with the introduction of anti-angiogenesis therapy, and patients now have effective treatment options that can prevent blindness and, in many cases, restore vision.

**BUT**

CURRENTLY THERE IS NO DRUG AVAILABLE FOR DRY AMD AND TREATMENT POSSIBILITIES ARE LIMITED TO LOW VISION REHABILITATION (LOW VISION AIDS AND LOW VISION INTRAOCULAR IMPLANTS)


SML - New Technology focuses on patients with advanced stage AMD but might be helpful also for patients with other macular diseases as well, e.g. myopic maculopathy, diabetic retinopathy or hereditary retinal diseases.

# SML . Scharioth Macula Lens

## SML – Surgery

---

- Using highly advanced modern surgical techniques
- Easy implantation: feasible for standard cataract surgeons, accessible to every cataract surgeon
- Microincision (2.2 mm)
- SML is placed in the sulcus
- The procedure takes only 10 minutes
- Pseudophakic patients
- SML is implanted MONOCULARLY in DOMINANT (better-seeing) EYE



## Which patients are suitable for SML?

- Any patient with DRY STAGE AMD complaining about near vision difficulties
- Other conditions may include diabetic retinopathy, myopic retinopathy, hereditary retinal diseases
- Distance vision better than 0.05 (ETDRS, decimal)
- Motivated patient
- PSEUDOPHAKIC PATIENTS or patients who are candidates for cataract surgery

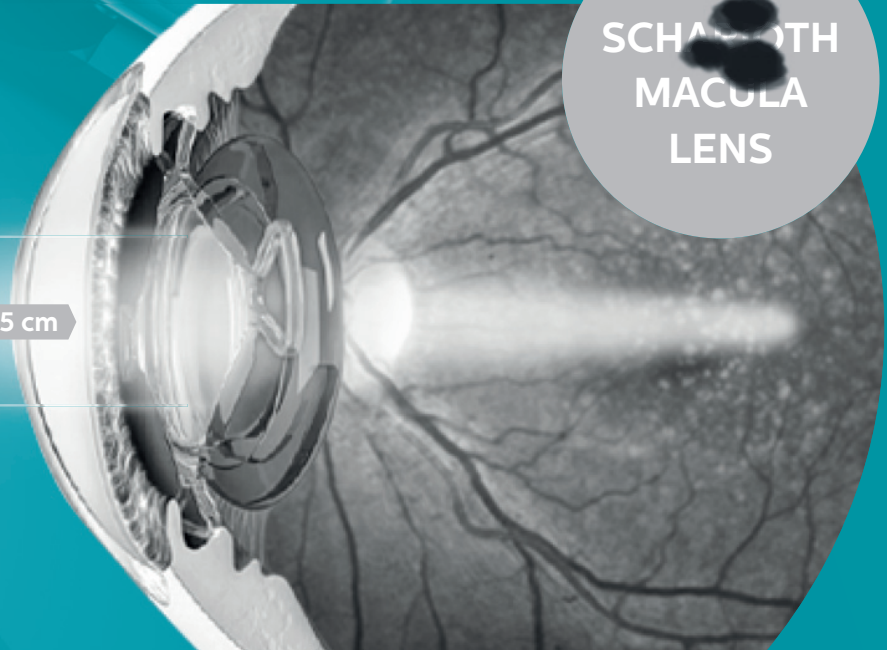


## SML: Magnifier in the EYE

SCHWABT  
MACULA  
LENS

SCHWABT  
MACULA  
LENS

Reading distance 15 cm



### Advantage of SML

Magnifying IOL system works, but not widely adapted because of

- Large incision
- Difficult surgery
- Might affect distance vision
- Affects visual field
- Only in combination with cataract surgery
- Limited magnification of intraocular Galilean telescope
- High cost
- Contraindicated in single-eyed patients (?)
- Limited reversibility

SML - New Technology focused on patients with advanced stage AMD

- Microincision (2.2 mm)
- Easy and safe surgery
- Distance vision not affected
- Visual field not affected
- May be implanted in pseudophakic or in patients or those who are candidates for cataract surgery
- Affordable (significantly lower cost)
- May be implanted in single-eyed patients
- Reversible

# SML . Scharioth Macula Lens


## What kind of preoperative tests are needed for SML indication?

### Simple preoperative SML candidate tests

- Near vision at 40 cm (+2.5D) vs 15 cm (+6.0D)
- Patient should understand the principle of reduced reading distance and feel improvement of near vision with +6.0
- PSEUDOPHAKIC PATIENT

SML IS POTENTIALLY SUITABLE FOR A LARGE PERCENTAGE OF EYE SURGEONS.  
NO EXTENSIVE TRAINING IS REQUIRED. THERE IS NO LEARNING CURVE.

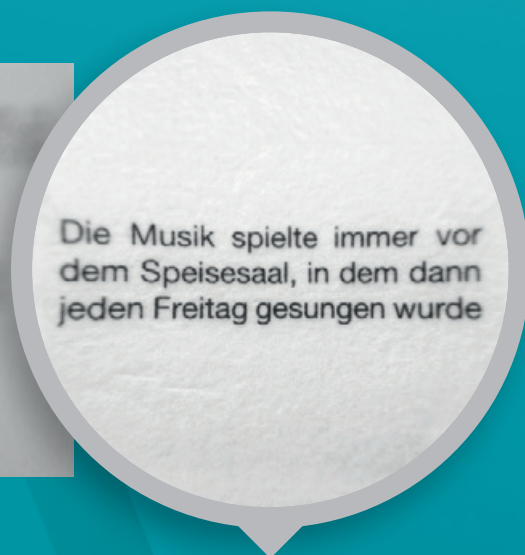
### Testing by Radner reading chart



At 40 cm



At 15 cm



Simulating SML (at 15 cm)



## SML in Life – self-contained patient



Patient using reading glasses



Patient using low vision aid



Patient using SML

The SML is not recommended in any of the following conditions:

- WET AMD (active/exudative stage)
- Zonulopathy, subluxation, aphakia
- Progressive glaucoma
- Active iris neovascularisation
- Shallow ACD

# SML . Scharioth Macula Lens

## Clinical evaluation assessing safety and efficacy of SML

---

**AIM:** To assess safety and efficacy of SML

### DESIGN

- Pilot study
- Prospective
- Interventional (single group assignment)
- 2 centers

### STUDY PLACE

- Prof. Gabor B. Scharioth (8 patients), Recklinghausen, Germany
- Prof. Pavel Rozsival (3 patients), Hradec Kralové, Czech Republic

### INTERVENTION

- 11 pseudophakic patients/11 eyes
- Monocular implantation
- Eyes with DRY AMD
- Follow-up: 3–6 months (between September 2013 – March 2015)

### INVESTIGATION

#### Preoperative

- BCDVA, BCNVA; simulation – NVA with addition of +6D from 15 cm distance
- Biomicroscopic examination; IOP
- Fundus examination, FAG

#### Postoperative

- BCDVA, UNVA,
- Biomicroscopic examination; IOP
- Fundus examination, FAG





## Pilot clinical evaluation proved the concept of SML

### Outcomes of the study:

- There was NO reduction in visual acuity
- Distance visual acuity was NOT affected
- Near vision improved in 11 eyes (tested with Radner reading chart)
- One patient out of 11 did not have improvement of NVA due to very low BCDVA before surgery (0.05; ETDRS)
- Most patients are able to read (newspaper)
- No complications related to surgery or implant occurred during follow-up period
- Overall satisfied patients

Patient	Preoperative BCDVA (ETDRS decimal)	Postoperative BCDVA (ETDRS decimal)	Pre BCVA (add +3.0D) (RADNER CHARTS)	Pre BCVA @ 15 cm (+6.0 D) (RADNER CHARTS)	Post UCVA @15 cm (SML) (RADNER CHARTS)
1*	0.4	0.4	6	4	1
2*	0.12	0.12	13	11	8
3*	0.4	0.4	5	3	1
4*	0.05	0.05	13	13	13
5*	0.16	0.16	11	8	5
6*	0.2	0.2	11	8	4
7*	0.1	0.1	11	8	7
8*	0.5	0.5	7	4	3
9**	0.3	0.3	9	5	1
10**	0.3	0.3	13	5	5
11**	0.3	0.3	8	1	1
<b>MEAN</b>	<b>0.257</b>	<b>0.257</b>	<b>9.727</b>	<b>6.36</b>	<b>4.36</b>

DISTANCE VISION NOT AFFECTED

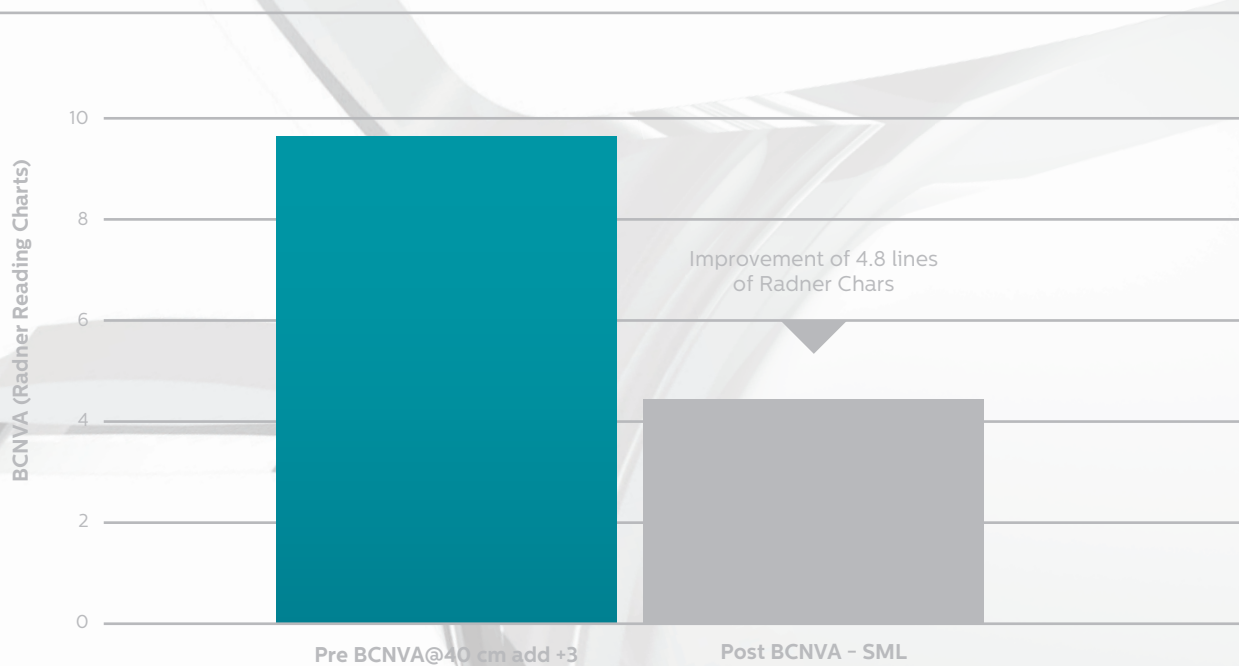
SIGNIFICANT IMPROVEMENT OF NEAR VISION

Graph shows significant improvement of mean near visual acuity – improvement of 4.4 lines of Radner Charts in patients after implantation with SML compared to patients before surgery.

\*Data published by Prof. Gabor B. Scharioth; ESCRS, London 2014; \*\* Data published by Prof. Pavel Rozsival, Live surgery, Prague, 2015.


# SML . Scharioth Macula Lens

## MEAN BCNVA

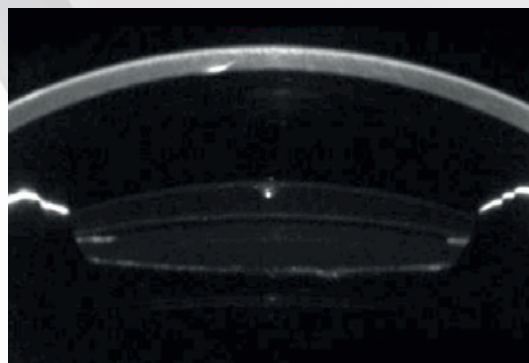


Significant improvement of mean near visual acuity – improvement of 4.4 lines of Radner Charts in patients after implantation with SML compared to with patients before surgery.

## Accurate and stable implant position



Postoperative image in retro-illumination, demonstrating excellent centration of Scharioth Macula Lens; note central "raindrop" (diameter 1.5 mm).



Scheimpflug image of anterior segment, perfect positioning of Scharioth Macula Lens; note clear space between the two lenses. Courtesy of Prof. Gabor B. Scharioth.

# REFERENCES



1. WHO causes of blindness. 2008.
2. Agarwal A, Lipshitz I, Soosan J, Mandeep L, Rahul T, Kumar AD, Agarwal A.: **Mirror telescopic intraocular lens for age-related macular degeneration.** Design and preliminary clinical results of the Lipshitz macular implant. *J Catar Refr Surg*, 2008; 34; 87-94.
3. A.Calabrése, JB Bernard, L. Hoffart, G. Faure, F. Barouch, J.Conrath, E. Caster: **Wet versus Dry Age-Related Macular Degeneration in Patients with Central Field Loss:** Different Effects on Maximum Reading Speed. *Investigative Ophthalmol & Visual Science*, April 2011, Vol.52, No. 5.
4. Lipshitz, I, Loewenstein, A, Reingewirtz, M, and Lazar, M. **An intraocular telescopic lens for macular an intraocular telescopic lens for macular degeneration** *Ophthalmic Surg Lasers*. 1977; 28: 513–517.
5. Age-Related Eye Disease Study Research Group. **Potential public health impact of age-related eye disease study results; AREDS report no. 11** *Arch Ophthalmol*. 2003; 121: 1621–1624.
6. Rosner, M., Ben-Simon, G., and Sachs, D. **Feasibility and safety of laser treatments in eyes with an intraocular implantable miniature telescope.** *J Cataract Refract Surg*. 2003; 29: 1005–1010.
7. Agarwal, A. **Consultation section: cataract surgical problems.** *J Cataract Refract Surg*. 2007; 33: 183–185.
8. Riusala, A., Sarna, S., and Immonen, I. **Visual Function Index (VF-14) in exudative age-related macular degeneration of long duration.** *Am J Ophthalmol*. 2003; 135: 206–212.
9. Kaskaloglu, M., Üretmen, Ö, and Yağcı, A. **Medium-term results of implantable miniaturized telescopes in eyes with age-related macular degeneration.** *J Cataract Refract Surg*. 2001; 27: 1751–1755.
10. Alió, J.L., Mulet, E.M., Ruiz-Moreno, J.M. et al. **Intraocular telescopic lens evaluation in patients with age-related macular degeneration.** *J Cataract Refract Surg*. 2004; 30: 1177–1189.
11. Koziol, J, Peyman, G.A, Cionni, R et al. **Evaluation and implantation of a teledioptic lens system for cataract and age-related macular degeneration.** *Ophthalmic Surg*. 1994; 25: 675–684.
12. Peli, E. **The optical functional advantages of an intraocular low-vision telescope.** *Optom Vis Sci*. 2002; 79:225-233.
13. Goldstein, H. **The reported demography and the causes of blindness throughout the world.** *Adv Ophthalmol*. 1980; 40: 1-99.
14. Hengerer FH, Artal P, Kohnen T, Conrad-Hengerer I. **Initial Clinical Results of a New Telescopic IOL Implanted in Patients With Dry Age-Related Macular Degeneration.** *J Refract Surg*. 2015;31(3):158-162.
15. K. Michalska-Malecka, A. Kabiesz, M. Nowak, D. Spiewak: **Age related macular degeneration – challenge for future:** Pathogenesis and new perspectives for treatment.
16. Friedman DS, O’Colmain BJ, Muñoz B, Tomany SC, McCarty C, de Jong PT, Nemesure B, Mitchell P, Kempen J. Eye Diseases Prevalence Research Group. **Prevalence of age-related macular degeneration in the United States.** *Arch Ophthalmol*. 2004;122:564–572.
17. Vingerling JR, Dielemans I, Hofman A, Grobbee DE, Hijmering M, Kramer CF, de Jong PT. **The prevalence of age-related maculopathy in the Rotterdam Study.** *Ophthalmology*. 1995;102:205–210.
18. Klein R, Knudtson MD, Lee KE, Gangnon RE, Klein BE. **Age-period-cohort effect on the incidence of age-related macular degeneration: the Beaver Dam Eye Study.** *Ophthalmology*. 2008;115:1460–1467.
19. Klein R, Klein BE, Lee KE, Cruickshanks KJ, Gangnon RE. **Changes in visual acuity in a population over a 15-year period: the Beaver Dam Eye Study.** *Am J Ophthalmol*. 2006;142:539–549.
20. Parmeggiani F, Romano MR, Costagliola C, Semeraro F, Incorvaia C, D’Angelo S, Perri P, De Palma P, De Nadai K, Sebastiani A. **Mechanism of inflammation in age-related macular degeneration.** *Mediators Inflamm*. 2012;2012:546786.
21. Tien Y, Wong, Xiang LI, Xinyi Su, Gemmy C. Cheung, Ching-Yu Cheng: **The number and distribution of People with Age-Related Macular degeneration Worldwide in 2020 and 2040:** A Systematic Review and Hierarchical Bayesian Meta-Analysis. Program NO: 220; Poster Board Nu:DO065; ARVO 2013.
22. Wan Ling Wong, Xinyi Su, Xiang Li, Chui Ming G Cheung, Ronald Klein, Ching-Yu Cheng, Tien Y. Wong: **Global prevalence of age related macular degeneration and disease burden projection for 2020 an 2040: a systematic review and meta-analysis.** *Lancet Glob Health* 2014;2:e106-16; publishe on-line January 3, 2014.
23. Yalin Mu, Manli Zhao, Guangming Su: **Stem cell-based therapies for age-related macular degeneration: current status and prospects.** *Int J Clin Exp Med* 2014;7(11):3843-3852.
24. Scharioth GB, “Add-on IOLs for Vitrectomized Silicone oil-filled Eyes,” *Retinal Physician* May 2014; 11:31–33. Available at: <http://www.retinalphysician.com/articleviewer.aspx?articleID=111129>.
25. Sauder G, Cordes A. **Scope of applications and experience record with a new generation of add-on IOLs: the A4W lens.** *Ophthalmol-Chirurgie* 2012; 24(suppl. 2):1–6. Available at: [http://www.1stq.de/media/raw/A4W\\_Englisch\\_AddOn\\_OphthalmolChirurgie\\_engl.pdf](http://www.1stq.de/media/raw/A4W_Englisch_AddOn_OphthalmolChirurgie_engl.pdf).

# MEDINOVA

> oftalmologia

via Antiniana, 2i | 80078 Pozzuoli | NA (Italy)

tel. +39 081 770 73 27 / +39 081 770 31 98 | fax +39 081 546 32 99

info@medinovasrl.com / www.medinovasrl.com

**MEDI**  **NTUR**  
Vision of Expertise

**MediContur**  
Medical Engineering Ltd  
export@medicontur.com  
www.medicontur.com

**Head Office**  
Herceghalmi Road  
2072 Zsámbék  
Hungary

**International Office**  
Chermin des Aulx 18  
1228 Plan-les-Ouates  
Geneva / Switzerland

**CE**  
0120